



Type of the Paper (Article)

Hepatoprotective Activity of *Oxalis stricta* linn. on Paracetamol Induced Hepatotoxicity in Albino Rats

Sohankumar Anilbhai Patel ^{1,*}, S. V. Rajendra ², S. Ramchandra Setty ³

Department of Pharmacology & Toxicology,

¹Shri B. M. Shah College of Pharmaceutical Education & Research, College Campus,
Modasa-383315, Gujarat, India

²Krupanidhi College of Pharmacy, Bangalore, Karnataka, India

³Govemrnt College of Pharmacy, Bangalore, Karnataka, India

*Author to whom correspondence should be addressed; E-Mail: sohanpharma_31@yahoo.co.in
Tel.: +91-9408411868

Received: 11/12/2015

/Accepted: 12/02/2016

Abstract: This study was designed to determine the hepatoprotective effects of Ethanolic Extract of *Oxalis stricta* Linn.(EEOS) towards Paracetamol intoxicated hepatic damage in Albino rats. The various extracts were prepared dose form 250 mg/kg and 500mg/kg against liver toxicity induced by Paracetamol at a dose of 2 gm/kg p.o once daily. Serum glutamate pyruvate transaminase (SGPT), serum glutamate oxaloacetate transaminase (SGOT), alkaline phosphatase (ALP) and bilirubin content which was elevated due to Paracetamol intoxication was significantly reduced by the extract. Standard drug Silymarin was used as reference. In Paracetamol alone treated animals shows lipid peroxidation was increased with decrease in superoxide dismutase (SOD), catalase (CAT), reduced glutathione (GSH) levels which represents the hepatic antioxidant status. It was further confirmed by histopathological observations. Futher Histopathological observations indicated. From the results it may be concluded that the 70% ethanolic extract of *Oxalis stricta* Linn. Possess hepatoprotective activity.

Keywords: *Oxalis stricta* Linn, Paracetamol, Hepatoprotective Activity, Silymarin.

I. Introduction

Liver is larger organ, several multi functions in body. Liver disease is common metabolic disorder affecting the world population. The human beings are constantly exposed to various environmental, occupational and xenobiotics challenges due to modern life styles. The various free radicals that are released in to the body are superoxide anion (O_2^{\bullet}), NO radical, NOO^{\bullet} , OH^{\bullet} and H_2O_2 radical. The liver serves both as an exocrine and an endocrine gland. The liver injury may take several forms and involve the hepatocytes, vascular cells or bile ducts [1].

Paracetamol (N-acetyl-p-aminophenol) is a widely used analgesic and antipyretic drug and is safe when used in therapeutic doses. However, over dosage of paracetamol is known to be hepatotoxic and nephrotoxic in man and in experimental animals. At lower doses, about 80% of ingested paracetamol is eliminated mainly as sulfate and glucuronide conjugates before oxidation and only 5% is oxidized by hepatic cytochrome P450 (CYP2E1) to a highly reactive and toxic electrophile i.e. N-acetyl-p-benzoquinimine (NAPQI). After over dosage of paracetamol the glucuronidation and sulfation routes become saturated and as a consequence, paracetamol is increasingly metabolized into NAPQI. Also NAPQI is detoxified by glutathione (GSH) to form 3-(GSH-S-yl) acetaminophen. Paracetamol overdose saturates the nontoxic metabolic pathway, i.e. sulfation, glucuronidation, and

detoxification of NAPQI by glutathione. The reactive NAPQI may oxidize and arylate cysteinyl thiol group, forming adducts which inhibit the function of cellular proteins. Adducts formation has been demonstrated for a selenium-binding protein, for microsomal subunit of glutamine. Other mechanism, such as oxidation of pyridine nucleotides and lipid peroxidation, may contribute to cell damage by paracetamol overdose [2-4].

Oxalis stricta Linn. The literature survey reveals that the plant has been used for stomach cramps, nausea, common cold, to reduce risk of the stroke & fever, Uses in the cooling, to cure scurvy and diuretics, Also used in the diaphoretics and anthelmintics, Used in inhibit absorption of calcium. , Oral aid infusion of plant used as wash to refresh the mouth, Used as anti-witch medicine, Relieves for thirst and applied for swelling, Used in stimulating appetite, ulcer of mouth and cancer treatment. The different species of *Oxalis stricta* Linn. Contains Oxalic acid, calcium oxalate, potassium. Oxalate, vitamin A and ascorbic acid [5-7].

II. Experimental Section

II.1. Plants Materials

Oxalis stricta Linn. plants were collected from Botanical garden of S.C.S college of pharmacy. Harapanahalli, Davangere district of Karnataka. The plant is identified and authenticated by Prof. K. Prabhu, Department of Pharmacognosy, S.C.S. College of Pharmacy, Harapanahalli, Davangere dist, Karnataka.

II.2. Preparation of Extracts

The plants were shade dried separately at room temperature and pulverized. The powder obtained is subjected to successive soxhlet extraction with the solvents with increasing order of polarity i.e. Petroleum ether (60-80°), chloroform (59.5-61.5°), ethanol (64.5-65.5°) and water. In addition the shade-dried powder is extracted directly with 70% ethanol (hydro-alcoholic extract) after defatting with petroleum ether, which is used for Liver investigations, after subjecting it to preliminary qualitative phytochemical studies [8].

II.3. Preliminary phytochemical analysis

The different extracts were subjected to preliminary phytochemical analysis to assess the presence of various phytoconstituents.

II.4. *In Vivo* hepatoprotective activity

II.4.1. Selection of Animals

Albino rats (wistar) weighing 150-200g and albino mice weighing 20-25g of either sex were used in this study. They were procured from Sri Venkateshwara Enterprises, Bangalore. The animals were acclimatized for one week under laboratory conditions. They were housed in polypropylene cages and maintained at 27°C ± 2°C under 12 hrs dark / light cycle. They were fed with standard rat feed (Gold Mohur Lipton India Ltd.) and water ad libitum is provided. The litter in the cages is renewed thrice a week to ensure hygiene and maximum comfort for animals. Ethical clearance for handling the animals is obtained from the Institutional animal ethical committee approved (Reg. no. 157/99/CPCSEA) at SCS college of pharmacy, prior to the beginning of the project work [9].

II.4.2. Evaluation of hepatoprotective activity in Paracetamol induced hepatotoxicity

The method of R.R. Chattopadhyay is followed[10]. In the dose response experiment, albino rats were randomly assigned into 5 groups of 6 individuals each. Group-I : Negative control (received vehicle 1 ml/kg s.c.), Group-II: Positive control (paracetamol 2 gm/kg p.o.), Group-III: Standard (Silymarin 25 mg/kg p.o.), Group-IV: EEOS (250 mg/kg p.o.), Group-V : EEOS (500 mg/kg p.o.). On 5th day, 30 min after the administration of Gum acacia, 100 mg/kg silymarin, 70% ethanolic extract 250 mg/kg and 70% ethanolic extract 500 mg/kg of *Oxalis stricta* Linn. plants to Group-II, III, IV and V respectively, paracetamol 2g/kg is given orally. After 48 hours of paracetamol feeding, rats were sacrificed under mild ether anesthesia. Blood samples were collected for evaluating the serum biochemical parameters. The liver sample is dissected out, blotted off blood, ished with saline for liver weight, liver

volume, GSH estimation and LPO estimation and also stored in 10% formalin and preceded for histopathology to evaluate the details of hepatic architecture in each group microscopically. The blood so collected is centrifuged immediately to get clear serum and is subjected to various biochemical studies.

II.5. in vivo anti-oxidant Activity

II.5.1. GSH estimation in Paracetamol induced hepatotoxicity

Tissue samples were homogenized in ice cold Trichloroacetic acid (1 gm tissue plus 10 ml 10% TCA) in an ultra turrax tissue homogenizer. Glutathione measurements were performed using a modification of the Ellman procedure (Aykae, *et. al.*). Briefly, after centrifugation at 3000 rpm for 10 minutes, 0.5 ml supernatant is added to 2 ml of 0.3 M disodium hydrogen phosphate solution. A 0.2 ml solution of dithiobisnitrobenzoate (0.4 mg/ml in 1% sodium citrate) is added and the absorbance at 412 nm is measured immediately after mixing. % increase in OD is directly proportional to the increase in the levels of Glutathione. Hence, % increase in OD is calculated[11].

II. 5.2. In vivo lipid peroxidation in Paracetamol induced hepatotoxicity.

The degree of lipid peroxide formation is assayed by monitoring thiobarbituric reactive substance formation [11, 12]. Stock solution of TCA-TBA-HCl reagent: 15% w/v trichloroacetic acid; 0.375% w/v thiobarbituric acid; 0.25N hydrochloric acid. This solution may be mildly heated to assist in the dissolution of the thiobarbituric acid. Combine 1.0 ml of biological sample (0.1-2.0 mg of membrane protein or 0.1-0.2 μ mol of lipid phosphate) with 2.0 ml of TCA-TBA-HCl and mix thoroughly. The solution is heated for 1 hr in a boiling water bath. After cooling, the flocculent precipitate is removed by centrifugation at 1000 rpm for 2 min. The absorbance of the sample is determined at 535 nm against a blank that contains all the reagents minus the lipid. The malondialdehyde concentration of the sample can be calculated by using an extinction coefficient of $1.56 \times 10^5 \text{ M}^{-1} \text{ cm}^{-1}$.

II.6. Biochemical markers in Paracetamol induced hepatotoxicity

Blood samples were collected for evaluating the following serum biochemical parameters. Serum glutamate pyruvate transaminase (SGPT), Serum glutamate oxaloacetate transaminase (SGOT), Serum alkaline phosphatase (ALP), Serum total bilirubin, Serum direct bilirubin were measured using assay kits. The extent of hepatocyte necrosis was determined with these activities as markers [13,14].

II.7. Histological studies

The liver sample is dissected out, blotted off blood, washed with saline then stored in 10% formalin and preceded for histopathology to evaluate the details of hepatic architecture in each group microscopically [15].

II.8. Statistical analysis

The data were analyzed using one way analysis of variance (ANOVA), using statistical software Graph Pad In Stat version 3.06. P values of < 0.05 were considered as statistically significant.

III. Results and Discussion

III.1. Preliminary Phytochemical investigation

It is observed from the preliminary photochemical screening of the plant that alkaloids, proteins and carbohydrates are absent in all the extracts. Moreover it is found that glycosides, flavonoids, tannins, are present in ethanolic, aqueous and hydro-alcoholic (30:70) extracts. It was qualitatively observed that 70% ethanolic extract contain higher concentration of polyphenolic components and hence selected this extract for further study.

III.2. Toxicity study

Before screening the test extract for in hepatoprotective activity, the extract was subjected to acute toxicity as per OECD guidelines no. 420 (fixed dose method). The extract was found to be toxic at 5000 mg/kg and non toxic at 2000 mg/kg as indicated by the mortality in the treated group. Hence, the 2500 mg/kg was treated as cutoff tolerable dose, 1/10th (250 mg/kg) and 1/5th (500 mg/kg) of this dose were selected for the further study.

III.3. Biochemical markers in Paracetamol induced hepatotoxicity

The hepatoprotective activity was assessed by measuring the biochemical markers like SGPT, SGOT, bilirubin (total and direct) and ALP in Paracetamol induced hepatotoxic models. Further the wet liver weight and liver volume; histopathological observations were made to assess hepatotoxicity/hepatoprotectivity. Show in Table 1.

Table 1. Effects of 70% EEOS on liver weight, liver volume and biochemical markers in Paracetamol induced hepatotoxicity

Treatment	Biochemical parameters Mean \pm SEM						
	Liver						
	Volume (ml/100)	Weight (g/100g)	SGOT IU/L	SGPT IU/L	ALP IU/L	Total Bilirubin mg/dl	Direct Bilirubin mg/dl
Negative Control (1ml vehicle)	6.34 \pm 0.508	6.24 \pm 0.508	215.33 \pm 15.149	83.51 \pm 8.738	252.73 \pm 17.99	0.81 \pm 0.038	0.18 \pm 0.007
Positive Control Paracetamol (2 g/kg p.o.)	6.31 \pm 0.283	6.12 \pm 0.278	325.11 \pm 7.458	281.66 \pm 9.418	416.78 \pm 13.591	2.60 \pm 0.175	0.85 \pm 0.050
Paracetamol + Standard (Silymarin) (2 g/kg p.o. + 100 mg/kg p.o.)	7.05 \pm 0.444***	6.91 \pm 0.430***	96.34 \pm 3.859***	104.95 \pm 4.833***	113.48 \pm 3.959***	0.85 \pm 0.053***	0.31 \pm 0.020***
Paracetamol + 70 % ethanolic extract (2 g/kg p.o. + 250 mg/kg p.o.)	6.38 \pm 0.0402 ^{ns}	6.20 \pm 0.424**	284.72 \pm 6.949*	213.41 \pm 7.67***	342.26 \pm 9.777*	1.28 \pm 0.029***	0.58 \pm 0.013***
Paracetamol + 70% ethanolic extract (2 g/kg p.o. + 500 mg/kg p.o.)	6.17 \pm 0.289*	6.0 \pm 0.260***	248.20 \pm 7.699***	188.33 \pm 4.987***	265.08 \pm 7.149***	0.81 \pm 0.144***	0.46 \pm 0.013***

Values are the mean \pm S.E.M. of six rats/ treatment.

Significance * $P < 0.05$, ** $P < 0.01$, *** $P < 0.001$, compared to paracetamol treatment

III.4 Tissue GSH and LPO levels in Paracetamol induced hepatotoxicity: Treatment with hydro-alcoholic extract of *Oxalis stricta* (250 mg/kg and 500 mg/kg b.w.) prevented depletion of GSH Level. Shows in Table 2.

Table 2. Effect of 70% ethanolic extract of *Oxalis stricta* (70% EEOS) on tissue GSH levels in Paracetamol induced hepatotoxicity

Treatment	Absorbance Mean \pm SEM	% Increase
Negative Control (1ml vehicle)	0.934 \pm 0.012	--
Positive Control Paracetamol (2 g/kg p.o.)	0.390 \pm 0.024	--
Paracetamol + Standard (Silymarin) (2 g/kg p.o. + 100 mg/kg p.o.)	0.763 \pm 0.035***	94.87
Paracetamol + 70% EEOS (2 g/kg p.o. + 250 mg/kg p.o.)	0.508 \pm 0.030***	28.20
Paracetamol + 70% EEOS (2 g/kg p.o. + 500 mg/kg p.o.)	0.621 \pm 0.035***	58.97

Values are the mean \pm S.E.M. of six rats/treatment.

Significance *** P<0.001, compared to paracetamol treatment.

Treatment with 70% ethanolic extract (250 mg/kg and 500 mg/kg b.w.) reduced the lipid peroxidation level. Show in Table 3.

Table 03. Effect of 70% EEOS on in vivo LPO in paracetamol induced hepatotoxicity.

Treatment	Absorbance Mean \pm SEM	% inhibition
Negative Control (1ml vehicle)	0.198 \pm 0.009	--
Positive Control Paracetamol (2 g/kg p.o.)	0.613 \pm 0.018	--
Paracetamol + Standard (Silymarin) (2 g/kg p.o. + 100 mg/kg p.o.)	0.192 \pm 0.017***	68.62
Paracetamol + 70% EEOS (2 g/kg p.o. + 250 mg/kg p.o.)	0.414 \pm 0.061**	32.41
Paracetamol + 70% EEOS (2 g/kg p.o. + 500 mg/kg p.o.)	0.254 \pm 0.016***	58.56

Values are the mean \pm S.E.M. of six rats/treatment.

Significance **P<0.01, ***P<0.001, compared to Paracetamol treatment.

III. IV Histopathology study:

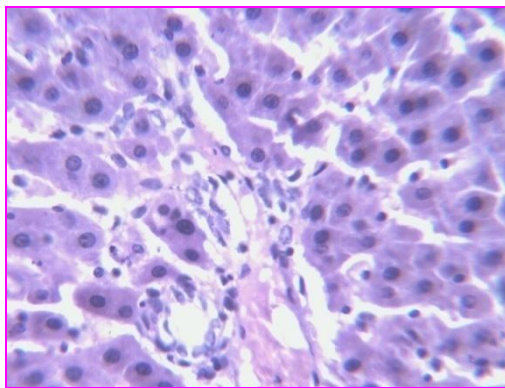


Figure 1. In the case of normal control (-ve control), hepatic globular structure, central vein, portal tract, sinusoids and kupffer cells were normal. Suggestive: **Normal liver.**

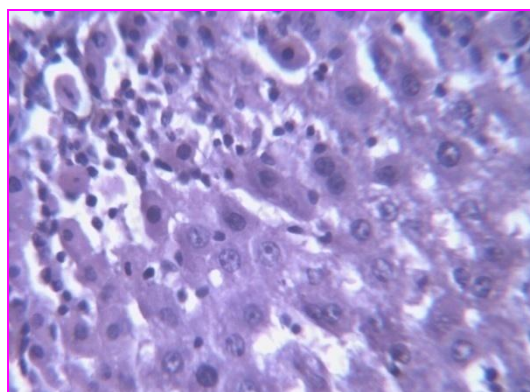


Figure 2. In the case of paracetamol treated group (+ve control), hepatic cells have shown moderate degree of fatty degeneration and ballooning of hepatocyte, fatty cyst, infiltration of lymphocytes and proliferation of kupffer cells. Liver sinusoids were congested. Severe inflammation in parenchyma was observed. Suggestive: **Fatty liver.**

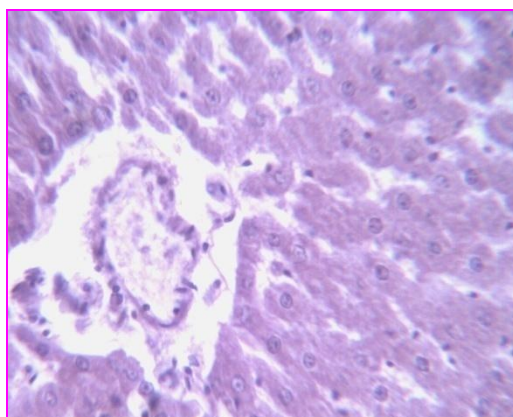


Figure 3: In the case of 100mg/kg silymarin treated group, the hepatic globular architecture was normal. There was mild inflammation. And other part was normal. Suggestive: **Regenerative changes in liver.**

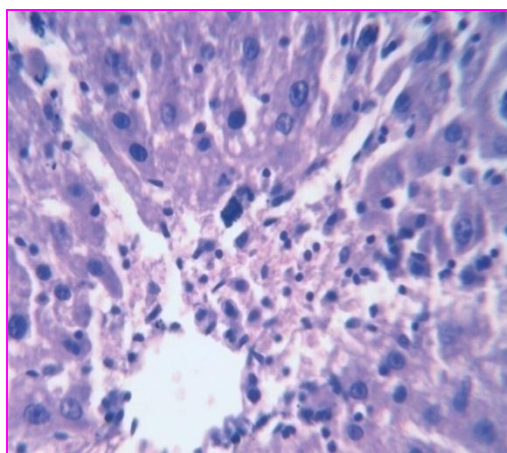


Figure 4. In the case of 250 mg/kg 70% ethanolic extract of *Oxalis stricta* treated group, Majority of hepatocyte were normal but there were less micro vascular fatty change with mild inflammation. Suggestive: **Light regeneration of hepatocyte.**

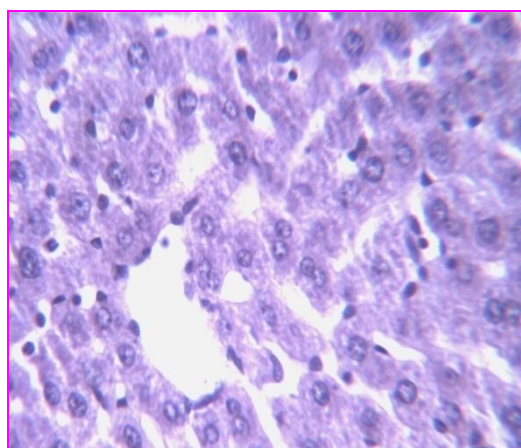


Figure 5. In the case of 500 mg/kg 70% ethanolic extract of *Oxalis stricta* treated group, the hepatic architecture was maintained. There was mild inflammation with normal hepatic cells. Suggestive: **Regeneration of hepatocyte.**

IV. Conclusion

The *Oxalis stricta* Linn. contains flavanoids, steroids, glycosides and tannins. 70% Ethanolic extract of *Oxalis stricta* Linn. demonstrated significant dose dependent increase in tissue GSH levels and reduction in lipid peroxidation in Paracetamol induced hepatotoxicity. Treatment with 70% Ethanolic extract of *Oxalis stricta* Linn. brought back the elevated levels of SGPT, SGOT, ALP, total and direct bilirubin in Paracetamol induced hepatotoxicity in rats to near normal levels. Histopathological observation revealed that treatment with 70% ethanolic extract has reversed the hepatic damage induced by Paracetamol. Hence the *Oxalis stricta* Linn. possess hepatoprotective activity. The 70% ethanolic extract of *Oxalis stricta* Linn. possess hepatoprotective due to the presence of tannins and flavanoids.

V. References

- [1] Harsh Mohan. Text book of Pathology. Vol. 5th ed. New Delhi; Jaypee Brothers Publication; 2005, 608-10.
- [2] Nell Kaplowitz. Drug-Induced Hepatotoxicity, Current Hepatology 1986; 6: 242-43.
- [3] Dipak V. Parmar, Gazala Ahmed, Milind A. Khandkar A, Surendra S. Katyara. Mitochondrial ATPase: a target for paracetamol-induced hepatotoxocity. Eur J Pharmacol 1995; 293: 225-29.
- [4] Sun-Mee Lee, Tai-Soon Cho, Dae-joong Kim, Young-Nam Cha. Protective effect of ethanol against acetaminophen induced hepatotoxicity in mice. Biochem Pharmacol 1999; 58: 1547-55.

- [5] J. K. Crellin, Jane Philpott, A. L. Tommie Bass. Herbal Medicine Past and Present: A reference guide to medicinal plants: 394-95.
- [6] Daniel E. Moerman. Native Medicinal Plants: An Ethnobotanical dictionary: 333-34.
- [7] Thomas M. Zennie and C.Dwayne Ogzewalla. Ascorbic acid and Vitamin A Content of Edible Wild Plants of Ohio and Kentucky. Journal Economic Botany 1997; 31:76-79.
- [8] Kokate CK. Practical Pharmacognosy Vol.4th ed. New Delhi: Vallabha prakashan, 1999: 149-56.
- [9] Prema Veeraraghavan. Expert consultant, CPCSEA, OECD guideline No. 420; Oct. 2000.
- [10] Chattopadhyay R.R. Possible mechanism of hepatoprotective activity of *Azadirachta indica* leaf extract: Part II. J. Ethnopharmacol 2003; 89: 217-219.
- [11] Maria Moron S. Levels of glutathione, glutathione reductase and glutathione S-transferase activities in rat lung and liver. Biochem. Et. Bioph. Acta 1979; 582: 67-78.
- [12] Aykae G, Vysal M, Yalein AS, Kocak-Toker N, Sivas A, Oz H. The effect of chronic ethanol ingestion on hepatic lipid peroxide, Glutathione, glutathione peroxidase and glutathione transferase in rats. Toxicology 1985; 36: 71-76.
- [13] John Buege A., Steven Aust D., Microsomal lipid peroxidation. London: Moury Kleiman Co.,1978 pp 302.
- [14] Chanchal K Roy, Jagadish V Kamath, Mohammad Asad. Hepatoprotective activity of *Psidium gujava* Linn. leaf extract. Indian J Exp Biol 2006; 44: 305-311.
- [15] Milind A Khandkar, Dipak V Parmar, Mita Das, Surendra S Katyare. Is activation of lysosomal
- [16] enzymes responsible for paracetamol-induced hepatotoxicity and nephrotoxicity. J Pharm Pharmacol 1996; 48: 437-440.

Please cite this Article as:

Sohankumar Anilbhai Patel, S. V. Rajendra, S. Ramchandra Setty, Hepatoprotective Activity of *Oxalis stricta* linn. on Paracetamol Induced Hepatotoxicity in Albino Rats, **Algerian J. Nat. Products**, 4:1 (2016) 233-240.

www.univ-bejaia.dz/ajnp

Online ISSN: 2353-0391

Editor in chief: Prof. Kamel BELHAMEL